

# Venous Sinus Stenting in Idiopathic Intracranial Hypertension: Results of a Prospective Trial

Marc J. Dinkin, MD, Athos Patsalides, MD, MPH

**Background:** Our goal was to evaluate the safety and efficacy of stenting of venous sinus stenosis (VSS) in patients with medically-refractory, medically-intolerant or fulminant idiopathic intracranial hypertension (IIH) in a prospective, observational study.

**Methods:** Thirteen patients with IIH who were refractory or intolerant to medical therapy or who presented with fulminant visual field (VF) loss underwent stenting of VSS at the transverse-sinus sigmoid sinus junction, using a Precise Pro carotid stent system (Cordis). Inclusion criteria included papilledema-related VF loss with mean deviation (MD) worse than or equal to  $-6.00$  dB, elevated opening pressure (OP) on lumbar puncture (LP), VSS (either bilateral or unilateral in a dominant sinus), and an elevated ( $\geq 8$  mm Hg) trans-stenotic gradient (TSG). The main outcome measures were pre- to post-stent change in symptoms related to intracranial hypertension, MD (in dB) on automated (Humphrey) VFs, grade of papilledema (1–5), retinal nerve fiber layer (RNFL) thickness as measured by spectral domain optical coherence tomography (SD-OCT), TSG (mm Hg), and OP on LP (cm H<sub>2</sub>O).

**Results:** Improvement or resolution of headaches occurred in 84.7% of patients, pulse-synchronous tinnitus in 100%, diplopia in 100%, and transient visual obscuration in 100%. Out of 26 eyes, 21 showed an improvement in MD, with an average improvement of  $+5.40$  dB. Of 24 eyes with initial papilledema, 20 showed an improvement in Frisen grade, (mean change in grade of 1.90). Of 23 eyes undergoing SD-OCT, 21 (91.3%) demonstrated a reduction in RNFL thickness, with a poststent mean thickness of  $90.48$   $\mu$ m. Mean change in OP was  $-20$  cm H<sub>2</sub>O (reduction in mean from 42 to 22 cm H<sub>2</sub>O) with all subjects demonstrating a reduction,

although a second stenting procedure was necessary in one patient. Complications of the stenting procedure included one small, self-limited retroperitoneal hemorrhage, transient head or pelvic pain, and one allergic reaction to contrast. No serious adverse events occurred.

**Conclusions:** Stenting of VSS is safe and results in reduction of intracranial pressure in patients with IIH. This is associated with improvement in papilledema, RNFL thickness, VF parameters, and symptoms associated with intracranial hypertension.

**Journal of Neuro-Ophthalmology** 2016;0:1–9

doi: 10.1097/WNO.0000000000000426

© 2016 by North American Neuro-Ophthalmology Society

**I**diopathic intracranial hypertension (IIH) is a disease of elevated intracranial pressure (ICP) found mostly in obese women of child-bearing age. Symptoms include headaches, pulse-synchronous tinnitus (PST), diplopia from associated sixth nerve palsies, and visual field (VF) loss of varying degrees resulting from papilledema. Permanent field defects may occur in up to 25% of cases (1). Weight loss has been shown to reduce the papilledema associated with IIH (2), and the long-practiced use of acetazolamide has recently been validated in a large multicenter trial of patients with mild VF loss (3). However, up to 2.9% of cases present with fulminant vision loss (4), and an additional 10% are refractory to medical treatment alone (5), requiring intervention with a surgical therapy aimed at a fast, dependable reduction in ICP (ventriculoperitoneal/lumboperitoneal shunts) or localized optic disc edema (optic nerve sheath fenestration [ONSF]).

Although IIH was first described as “meningitis serosa” by Quinke more than 120 years ago (6), its underpinnings remain mysterious, justifying its idiopathic moniker (7). Over the last 20 years however, it has become clear that most patients with IIH harbor stenosis along the transverse-sigmoid sinus junction (TSJ), either bilaterally or in one dominant sinus, most notable with 3D contrast-enhanced magnetic resonance imaging (8). These stenoses may be due to an intrinsic abnormality in the sinus wall, such as an arachnoid granulation, scar tissue or septation, in which case

Department of Ophthalmology (MJD), New York Presbyterian Hospital, Weill Cornell Medical College, New York, New York; and Division of Interventional Neuroradiology, Department of Neurological Surgery (AP), New York Presbyterian Hospital, Weill Cornell Medical College, New York, New York.

The authors report no conflicts of interest.

Supplemental digital content is available for this article. Direct URL citations appear in the printed text and are provided in the full text and PDF versions of this article on the journal's Web site ([www.jneuro-ophthalmology.com](http://www.jneuro-ophthalmology.com)).

Address correspondence to Marc Dinkin, MD, Department of Ophthalmology, 1305 York Avenue, 11th Floor Weill Cornell Medical College, New York Presbyterian Hospital, New York, NY 10021; E-mail: [mjd2004@med.cornell.edu](mailto:mjd2004@med.cornell.edu)

they appear as a focal region of stenosis, or may be extrinsic, occurring as a result of compression by elevated ICP, in which case there is a more tapered appearance. After King et al (9) demonstrated a trans-venous pressure gradient in patients with IIH, Higgins et al (10,11) demonstrated symptomatic improvement in 8 patients who underwent stenting of the stenosis. This was soon followed by Owler et al (12), who demonstrated a reduction in cerebrospinal fluid (CSF) opening pressure (OP) in 3 patients and resolution of papilledema in 2. Donnet et al (13) reported 10 patients, all of whom experienced normalization of OP and resolution of papilledema after stenting, although 1 had optic atrophy. In the experience of Bussière et al (14), headaches improved or resolved in 10/10 patients and papilledema improved in all, although 5/10 still had Frisen grade I papilledema, and 1 was left with optic atrophy. Ahmed et al (15) demonstrated resolution of papilledema in all 46 patients who presented with papilledema, cessation of headache in 35/43, and improvement in VFs in 23/30, although the results of perimetry were only described as mild, moderate, and severe. Several subsequent studies confirmed these findings (16–20).

Despite the growing literature on venous stenting, there remains much uncertainty about its safety and efficacy in patients with IIH, with the bulk of the studies to date lacking standard treatment protocols on a prospective basis. Out of 251 patients described in the literature, only 61 underwent poststenting lumbar puncture (LP) and, therefore, it is hard to know if symptomatic improvement is reflective of true improvement in ICP. Furthermore, few studies carefully analyzed pre- and post-VF perimetry.

We designed a prospective trial in which patients with IIH who were medically-refractory, medically-intolerant, or presented with fulminant vision loss and who had stenosis of the TSJ associated with a trans-stenotic gradient (TSG)  $>8$  mm Hg underwent placement of a unilateral venous stent. We analyzed its effects on patients' symptoms, papilledema, VF, mean deviation (MD), retinal nerve fiber layer (RNFL) thickness, and ICP as measured by LP.

## METHODS

Our study adhered to the tenets of the Declaration of Helsinki and was Health Insurance Portability and Accountability Act-compliant. Institutional Review Board (IRB) approval at Weill Cornell Medical College was obtained. An application for Investigational Device Exemption for use of Precise Pro carotid stent system (Cordis) in our trial was approved by the Food and Drug Association (FDA).

A literature search was performed using keywords IIH, venous stenosis, and stent in PubMed, and all available studies and case reports involving stenting for IIH were reviewed (see **Supplemental Digital Content**, Table E1, <http://links.lww.com/WNO/A206>).

Patients were diagnosed with IIH using the modified Dandy criteria. LP was performed either in the lateral decubitus position or prone if done under fluoroscopy. Inclusion criteria included an MD of worse than or equal to  $-6.00$  dB in at least 1 eye, and only patients who were refractory or intolerant to standard medical therapy or presented with fulminant vision loss were evaluated for inclusion in the trial. "Refractory to medical therapy" was defined as persistent or progressive VF loss despite escalation of acetazolamide to 1000 mg PO BID or topiramate 100 mg PO BID for  $\geq 2$  weeks. In patients refractory or intolerant to medical therapy, high-grade papilledema was not an inclusion criterion. Fulminant IIH at presentation was defined as acute VF loss to within the central  $5^\circ$  and/or a decrement in visual acuity to less than or equal to 20/50 in either eye, in the presence of grade 4 or 5 papilledema. Exclusion criteria included age less than or equal to 21 years, creatinine  $>1.5$  mg/dL, and/or creatinine clearance  $<60$  mL/min, acute shunt dysfunction in patients with prior CSF diversion procedures, severe allergic reaction to iodine contrast despite premedication with steroids, contraindication to general anesthesia, use of aspirin, clopidogrel or anticoagulants, thrombophilic disorder or antidiolipin syndrome, use of tetracycline derivative, oral contraceptives, or vitamin A within the last 3 months, dural arteriovenous fistula or other arteriovenous lesion affecting cortical venous flow, pregnancy, or absence of contraception in woman of child-bearing potential.

All patients underwent magnetic resonance venography or computed tomographic venography, and only those with  $>50\%$  bilateral venous sinus stenosis (VSS) at the TSJ or unilateral stenosis of a dominant sinus were considered for inclusion. Such patients then were offered ventriculoperitoneal shunting, ONSF, or evaluation for venous stenting. Informed consent was obtained from all patients.

### Catheter Venography/Manometry

A 2.3 French microcatheter was placed into the superior sagittal sinus (SSS) through the common femoral vein, using local anesthesia only. After venography with iodinated contrast material, measurement of the intrasinus pressures from the SSS to the jugular bulb was performed with the proximal end of the microcatheter connected to a pressure cable. A difference of  $\geq 8$  mm Hg between the proximal transverse and distal sigmoid sinuses was necessary to proceed.

### Venous Sinus Stenting

Under general anesthesia, an appropriately sized stent (8–10 mm diameter, 30–40 mm length) was placed across the stenosis immediately after the diagnostic angiogram in 12/13 patients. One patient returned on a separate day for stenting. If the stenosis was bilateral, the stent was placed in the nondominant cerebral hemisphere side. Poststent dural

venous sinus pressures were measured and the TSG was calculated. Ipsilateral common carotid artery angiogram was performed to ensure no delay or abnormal stasis of the superficial or deep venous drainage. Patients were observed for 24 hours in a neurological intensive care unit and 24 hours in stepdown unit. All patients were premedicated with aspirin 325 mg per day and clopidogrel 75 mg per day for at least 2 days; clopidogrel was continued for 1 month after the procedure, and aspirin for 6 months. After stenting, ICP-lowering medications were tapered, as tolerated.

### Clinical Evaluation

Patients completed questionnaires evaluating headache, PST, diplopia, and transient visual obscurations. For each symptom, a Likert scale was used to quantify the severity and frequency of the symptom (grades 0–5, 5 the most severe). All patients underwent a complete medical, neurological, and neuro-ophthalmological examination before the procedure, including dilated funduscopy and Humphrey perimetry using a SITA standard 24-2 algorithm. VFs were repeated until reliability indices were within normal. All patients but one underwent spectral domain optical coherence tomography (SD-OCT; Cirrus Zeiss Meditec, Dublin, CA) and fundus photography, either before the stenting or within 3 days of the procedure in emergency cases.

Patients returned for neuro-ophthalmic follow-ups including SD-OCT within the first 4 weeks, between 2 and 4 months, and at approximately 6, 9, 12, 18, and 24 months post procedure. Fundus photography was repeated at 3 and 6-month follow-ups. Repeat questionnaires were administered at approximately 3 months. All patients were weighed at each visit. Repeat LP was performed at approximately 3 months in all patients. Repeat venography was only performed if there was concern for stent thrombosis or new stenosis in patients with recurrent symptoms.

### Statistical Analysis

Pre- and post-stent data was compared using a paired *t* test, and confirmed by a one sample signed rank test. Patients were followed at regular intervals after stenting (at 1, 3, 6, 12, 18, and 24 mo), and then as needed. Mean duration of follow-up to date is 499 days (range: 65–1153 days).

## RESULTS

Ten patients fulfilled criteria and opted to proceed with the procedure. An additional 3 patients underwent placement of the stent outside of the protocol because of age ( $n = 2$ , age 18 and 20 years at presentation), and a history of chronic renal failure on hemodialysis ( $n = 1$ ), although subsequent amendments to the FDA and IRB allowed patients 18 or older, and those with renal failure on dialysis. These 3 patients were enrolled in a separate prospective registry for

data collection. All patients were followed prospectively according to the same timetable, and all patients underwent the same pre- and post-stent evaluation. All patients enrolled were found to have stenosis and a TSG  $>8$  mm Hg, and were treated with stenting.

Patient demographic data on previous treatment modalities are summarized in Table 1. Mean age was 29 years (range 18–39). All were female. Median weight was 97.7 kg (range 72.3–144.5). Reasons for requiring a surgical procedure were medically-refractory in 7 patients (53.8%), medication intolerance in 5 (38.5%), and fulminant vision loss in 3 (23.1%). Two (15.4%) had undergone procedures at least 5 months prior, including 1 (7.7%) lumboperitoneal shunt that became infected and was removed, and 1 (7.7%) bilateral ONSF.

### Prestenting Data

#### Baseline Symptoms

Thirteen patients (100%) complained of headache, 11 (84.6%) of PST, 6 (46.2%) of diplopia, 10 (76.9%) of transient visual obscurations (TVO), 1 (7.7%) of metamorphopsia, 2 (15.4%) of back pain, and 1 (7.7%) of hearing loss. Median quality of life questionnaire scores were 5 (range 2–5).

#### Baseline Examinations

Twenty-five eyes were analyzed and 1 was excluded because of a posterior capsular opacification (PCO) at baseline. Mean best-corrected visual acuity (BCVA) was 20/55 (range 20/15–20/800), but median acuity was 20/20, and mean Ishihara color plate score was 85% correct (range 0%–100%). Two eyes (8%) demonstrated a relative afferent pupillary defect. There was 1 patient (4%) with an incomitant esotropia due to a sixth nerve palsy. One patient (4%) had metamorphopsia on Amsler grid testing. Other than the PCO in 1 eye, anterior segment exam was normal in all. Funduscopy revealed papilledema in at least 1 eye in all patients, ranging from Frisen grade 1–5 (mean 2.44). VFs demonstrated a mean baseline MD of  $-12.27$  dB (range:  $-3.35$  dB to  $-33.77$  dB). SD-OCT performed in 23/26 eyes showed mean RNFL thickening ( $\geq 115$   $\mu\text{m}$ ) in 14/23 (61%) of eyes, and atrophy (mean RNFL  $\leq 79$   $\mu\text{m}$ ) in 4 (17%), with an average mean peripapillary RNFL thickness of 184  $\mu\text{m}$ .

#### Baseline Lumbar Puncture

Mean OP was 42.31 cm H<sub>2</sub>O (range: 28–77 cm H<sub>2</sub>O) with normal cerebrospinal composition in all patients.

#### Venography Results

Catheter venography revealed codominant venous sinus anatomy with bilateral stenosis in 8 patients (62%) and unilateral stenosis of the dominant TSJ in 5 (38%), 3 on the left and 2 on the right. Eight of 13 stenoses (61.5%) were extrinsic and 5/13 (38.5%) were intrinsic. Pre- and post-venous sinus stenting results are summarized in Table 2. Mean stenosis was 60% (range: 50%–80%). Mean TSG

**TABLE 1.** Demographic data and treatment modalities in patients with idiopathic intracranial hypertension

Pt	Demographics			BMI (kg/m <sup>2</sup> )		Medications	
	Age (y)/ Gender	Treatment Failure	Prior Surgery	Pre	Post	Pre	Post
1	27/F	Intolerance		30.7	27.78	ACTZ 250 mg/d	ACTZ 250 mg/d
2	20/F	Refractory	B/L ONSF	31.65	30.5	ACTZ 2 g/d	ACTZ 500 mg/d
3	18/F	Fulminant		28.4	29.4	ACTZ 1.5 g/d	None
4	39/F	Intolerance		37.11	36.94	None	None
5	29/F	Refractory		38.05	38.7	ACTZ 1 g/d, TPM 100 mg/d	None
6	28/F	Refractory		46.9	47	ACTZ 1.5 g/d	None
7	30/F	Intolerant		51.35	53.29	None	None
8	33/F	Intolerant		37.1	36.89	ACTZ 1 g/d	None
9	32/F	Refractory		33.8	35.16	ACTZ 1 g/d	ACTZ 1 g/d, TPM 50 mg/d
10	24/F	Refractory		35.33	39.6	ACTZ 2 g/d	ACTZ 500 mg/d
11	32/F	Fulminant		28.6	29.55	ACTZ 2 g/d	ACTZ 1.5 g/d
12	22/F	Intolerance	LPS	26.05	28.31	None	None
13	37/F	Fulminant		38.99	39.77	None	TPM 50 mg/d

ACTZ, acetazolamide; B/L, bilateral; BMI, body mass index; LPS, lumbo-peritoneal shunt; ONSF, optic nerve sheath fenestration; TPM, topiramate.

was 20.54 mm Hg (range: 13–37 mm Hg) decreasing to a mean of 2.8 mm Hg (range: 0–6 mm Hg) post stenting.

#### Follow-up Data

##### Symptoms

At 3 months, headaches were resolved in 4 patients (30.8%), improved in 7 (53.9%), and persistent in 2 (15.4%). All of 11 patients (100%) with PST reported complete resolution immediately after stent placement. Three of 6 patients (50%) with diplopia reported complete resolution and 3 (50%) reported improvement. Eight of 10 patients (80%) with TVO reported resolution and 2 (20%)

reported improvement. No patients reported worsening of any of these symptoms after stenting.

##### Changes in Quality of Life

All 13 patients reported an improvement in quality of life (QoL) post procedure over a mean period of 7.5 months (range 1–24 months) [see **Supplemental Digital Content**, Table E2, <http://links.lww.com/WNO/A207>]. Median quality of life score decreased from 5 to 1.

##### Examination: Acuity

Mean BCVA at first follow-up was 20/52 (range 20/15–20/800), and median acuity was 20/20. Out of 25 eyes, 12

**TABLE 2.** Data regarding cerebral venous sinus stenting in patients with idiopathic intracranial hypertension

Pt	Stenosis					Trans-Stenotic Gradient (mm Hg)			Opening Pressure (cm H <sub>2</sub> O)			
	Side Stented	% Stenosis	Length (mm)	Intrinsic/ Extrinsic	Stent	Pre	Post	Change	Pre	Post*	Change	% Change
1	R	70	25	Extrinsic	8 × 30	21	0	21	42	24	−18	−42.9
2	R	90	10	Intrinsic	9 × 40	17	4	13	35	23	−12	−34.3
3	R	70	20	Intrinsic	10 × 40	23	5	18	77	27	−50	−64.9
4	L	90	20	Extrinsic	9 × 40	20	3	17	38	23	−15	−39.5
5	R	80	25	Extrinsic	10 × 30	22	1	21	40	29	−11	−27.5
6	L	90	20	Intrinsic	9 × 20	17	4	13	43	20	−23	−53.5
7	L	80	40	Extrinsic	9 × 40	14	2	12	28	29, 21	+1, −8	+3.6, 228.6
8	R	90	15	Intrinsic	9 × 30	13	1	12	40	15	−26	−65.0
9	R	70	20	Intrinsic	9 × 40	24	6	18	55	15	−40	−72.7
10	R	90	35	Extrinsic	8 × 40	13	2	11	36	21	−15	−41.7
11	R	90	25	Extrinsic	8 × 40	27	0	27	40	26	−14	−35.0
12	R	70	20	Extrinsic	9 × 40	19	1	18	43	20	−23	−53.5
13	R	80	20	Extrinsic	8 × 40	37	4	33	33	18	−15	−45.5

\*For patient 7, the first poststent OP was in setting of new stenosis adjacent to stent. Second poststent OP followed placement of a second stent. L, left; OP, opening pressure; R, right.

improved, 4 worsened, and 9 were stable. BCVA never changed more than 2 lines on the visual acuity chart.

### Color Vision Testing

Average score on Ishihara plate testing was 93.2% compared with 85% at presentation.

### Visual Fields

Of 25 eyes, the average MD at follow up was  $-6.07$  dB right eye,  $-7.84$  left eye, and overall average  $-6.93$  dB. Twenty of 25 eyes (80%) improved. Mean improvement in MD was  $+5.34$  dB (range  $-3.73$  to  $+23.76$  dB; standard deviation  $6.44$  dB;  $P < 0.0001$ ). Of 5 eyes that did not improve, 3 worsened by less than  $1.00$  dB and 2 by less than  $4.00$  dB. In 1 eye with severe optic atrophy at presentation, the MD remained unchanged ( $-33.83$  from  $-33.72$  dB) (Fig. 1).

### Funduscopy

Twenty of 24 eyes with papilledema showed an improvement in Frisen grade and 4 showed no change. Mean Frisen grade improved from  $2.44$  (range 0–5) to  $0.54$  (range 0–2) with a mean change in grade of  $-1.90$  (range 0 to  $-5.00$ ; standard deviation  $1.51$ ;  $P < 0.0001$ ). Eleven of 13 patients experienced Frisen grade reduction in at least 1 eye.

### Spectral Domain Optical Coherence Tomography

Out of 23 eyes, 21 (91.3%) demonstrated a reduction in thickness of the RNFL. Two eyes (8.6%), normal at onset, thickened by a negligible amount (1 and  $3 \mu\text{m}$ , respectively). Mean poststent RNFL thickness was  $89.1 \mu\text{m}$  (range  $50$ – $123 \mu\text{m}$ ), decreased from prestant mean of  $205.4 \mu\text{m}$  (range

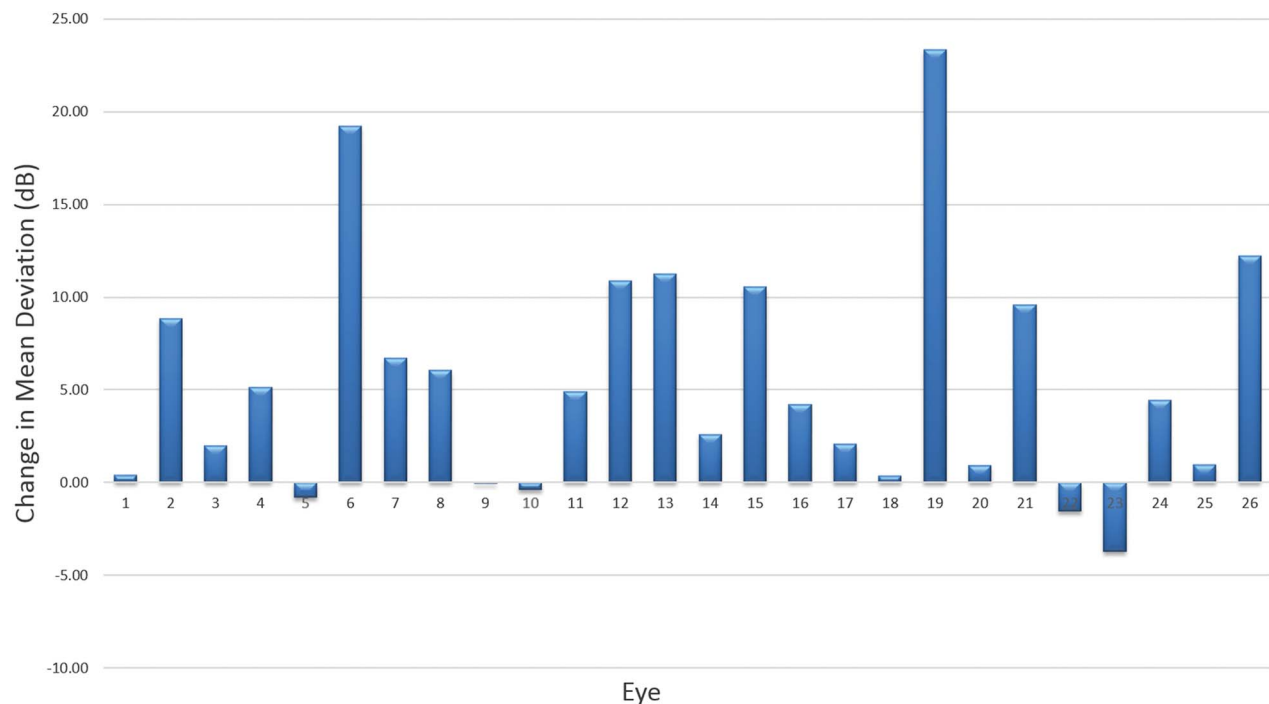
$55$ – $505 \mu\text{m}$ ). The mean change in thickness was  $116.3 \mu\text{m}$  (range  $+3$  to  $-382 \mu\text{m}$ ;  $P < 0.0001$ ) or  $38.51\%$  (range  $-3.37\%$  to  $77.8\%$ ). Four of 23 eyes (17.4%) demonstrated generalized atrophy (mean RNFL  $< 79 \mu\text{m}$ ) at presentation and in 2 eyes, the degree of atrophy worsened by more than  $5 \mu\text{m}$  at follow-up (18 and  $13 \mu\text{m}$ , respectively). RNFL thinning was never present at follow-up unless it was present at onset (see **Supplemental Digital Content**, Table E3, <http://links.lww.com/WNO/A208>).

### Lumbar Puncture

Mean follow-up OP was  $22 \text{ cm H}_2\text{O}$ , reduced from  $42 \text{ cm H}_2\text{O}$  prestant, with a mean change of  $-20.04 \text{ cm H}_2\text{O}$  (range  $-50$  to  $+1 \text{ cm H}_2\text{O}$ ;  $P = 0.0001$ ). OP was reduced in 12/13 patients (92.3%). One patient with unchanged OP had reported an improvement in symptoms after stent placement, but experienced recurrent headache for approximately 1 week before the repeat LP (3 months post stenting). This prompted a repeat venogram that demonstrated a new area of stenosis adjacent to the stent. A second stent was placed and symptoms improved. Repeat LP subsequent to the second stent showed a reduction of OP by  $7 \text{ cm H}_2\text{O}$ . Using this value for follow-up yielded a mean decrease in OP of  $20.65 \text{ cm H}_2\text{O}$ . The mean improvement in OP was  $14.75 \text{ cm H}_2\text{O}$  (38.8%) in the extrinsic group and  $30.2 \text{ cm H}_2\text{O}$  (58.1%) in the intrinsic group (Table 2).

### Medication Changes

Out of 13 patients, 3 (23.1%) were off all ICP-lowering medications (acetazolamide and topiramate) at presentation



**FIG. 1.** Change in visual field mean deviation (MD) at 3-month follow-up. A positive number signifies an improvement in MD; a negative number worsening MD.

and remained so at follow-up. An additional 5 (38.4%) started on medications, but were off by the time of the second LP, and 3/13 (23.1%) were on a reduced dosage. In 2 cases, low-dose topiramate (50 mg daily) was added for persistent headache. Thus at follow up LP, 11/13 patients were either on no ICP-lowering medication, or on a reduced dosage as compared to the initial LP.

**Changes in Weight**

Benefits of weight loss in IIH were explained to all patients at presentation. Out of 13 patients, 2 (15.4%) lost weight, 8 (61.5%) gained, and 3 (23%) remained within 3 pounds of their original weight over a mean period of 6.6 months (range 1–24 months). Mean change was +2.9 Kg.

**Procedural Complications**

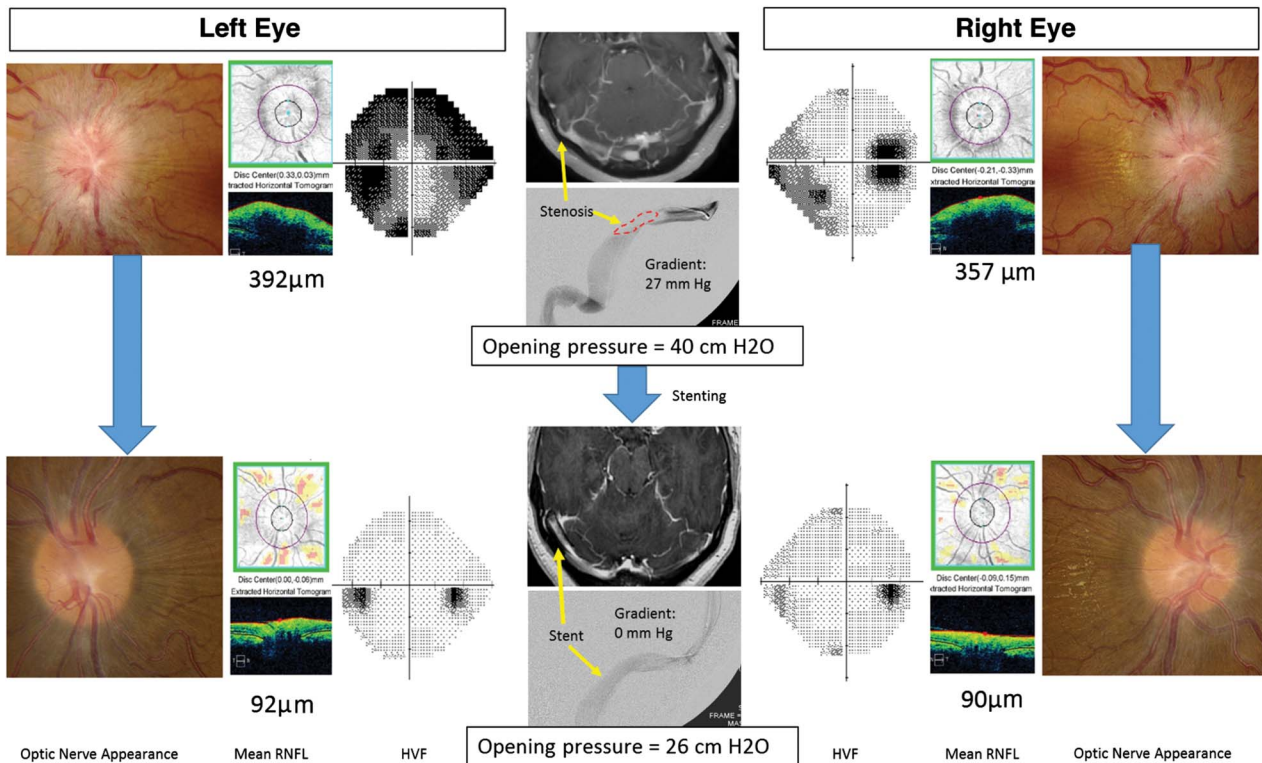
A small retroperitoneal hemorrhage at the site of the femoral puncture occurred in 1 patient and resolved spontaneously. A ruptured ovarian cyst was found in 1 patient a day after stenting, but the associated abdominal pain resolved within a few days. A majority of patients (6/13) experienced mild (n = 2), moderate (n = 2), or severe (n = 2) head pain ipsilateral to the side of the stent. In all cases, the headache differed in quality from their prestent headache and resolved within 3 days. In the immediate poststenting angiogram, 2 patients showed delayed flow in the vein of Labbe draining into the segment of the sinus treated with stenting. As

a precaution, we placed these patients on anticoagulation for 2 weeks, without sequelae. There were no cases of acquired hearing loss, intracranial hemorrhage, or stroke. Figure 2 displays the results for 1 patient after stenting.

**DISCUSSION**

We offer observational evidence from prospectively collected data, supporting the safety and efficacy of venous sinus stenting in patients with IIH who are refractory or intolerant to medical therapy or with a fulminant presentation. This is one of few studies (20) to quantitatively evaluate pre- and post-stenting VFs, and to assess optic disc edema using the Frisen scale. In addition, SD-OCT demonstrated the positive effect of stenting on papilledema-associated RNFL thickening, and our results are buttressed by poststent LP data in all patients, which has only been documented in 2 previous reports (13,17). We also demonstrated a uniform reduction in TSG after stent placement, as others have shown (12–20).

The relationship of IIH to VSS and venous hypertension remains controversial. Although the majority of IIH patients harbor VSS, the degree of stenosis does not correlate with the clinical course, degree of VF loss or OP on LP (21). Furthermore, CSF diversion procedures may reduce the stenosis (22) and venous hypertension (23) in IIH, suggesting that stenosis is simply a consequence of elevated ICP, although in some



**FIG. 2.** Patient 3. A 32-year-old woman presented with headaches, transient visual obscurations, and pulsatile tinnitus. All symptoms resolved after stenting except headache, which significantly improved, as did visual field testing, optic disc appearance and opening pressure on lumbar puncture. RNFL indicates retinal nerve fiber layer; HVF, Humphrey visual field.

studies, no improvement of stenosis has occurred with normalization of ICP (24), consistent with intrinsic VSS. Connor et al (25) demonstrated a reduced bony groove on which the transverse sinus rested in 8/23 IIH patients with stenosis, supporting an intrinsic etiology. Previously described models (26) support the idea put forth by Ahmed et al (15) that, even extrinsic, secondary stenosis can lead to further elevated ICP, which in turn leads to further stenosis, resulting in a positive feedback loop. The success demonstrated in our study and those done previously supports the notion that a reduction in VSS and venous pressure results in reduction of ICP.

We did not observe any correlation between either the length or degree of venous sinus stenosis and improvement in OP on LP with stenting. However, the degree of improvement in OP was higher in the group with intrinsic stenosis, with 4 of 5 patients demonstrating the greatest improvement in OP. Therefore, it appears that reversal of intrinsic stenosis may have a greater effect on ICP than that of extrinsic compression, where other factors likely play a role.

The frequency of a new stenosis in our series (1/13, 7.7%) was similar to that of Ahmed et al (15), where it occurred in 6 of 52 patients (11.5%). The clinical failure associated with the new stenosis and subsequent improvement in ICP and symptoms with its treatment lend further credence to the value of repeat stenting in these patients.

Of concern was the delayed flow into cortical veins in our 2 patients on the immediate poststent angiogram, given the risk of secondary cortical vein thrombosis and intracerebral hemorrhage. The one case in the literature where cortical venous blockage by a stent caused thrombosis and hemorrhage (13), occurred before the use of peri-procedural antiplatelet therapy, and was in a patient where the stent was being used to treat an arteriovenous malformation. In our review of the literature, we found only one case of death immediately after stent placement, and stent-related cortical venous stasis may have played a role in the observed malignant intracranial hypertension (27). Levitt et al (28) found no immediate effect on the vein of Labbe drainage, although the stent spanned the venous ostium in 92.1%. Despite these reassuring data, we recommend attention to cortical venous flow after the procedure, and anticoagulation if there is significant slowing.

The majority of eyes in our series demonstrated a reduction in Frisen grade of papilledema within weeks of stent placement, with the only exceptions being 4 eyes with grade I or II papilledema which did not change. However, follow-up LP showed normalization or reduction  $>10$  cm H<sub>2</sub>O in all of these patients, and SD-OCT at presentation demonstrated RNFL thinning, consistent with chronic changes which were unlikely to improve. Persistence of some degree of papilledema is seen after other ICP-lowering procedures including CSF diversion therapy and ONSF (29,30), as well. Therefore, the presence of mild peripapillary changes alone cannot be used as a reliable guide of whether or not a procedure was successful, and therefore future trials assessing venous stenting for IIH would benefit from follow-up LP to assess ICP.

Our study demonstrated a reduction in RNFL in all eyes with thickened RNFL at presentation, except in 1 patient, with improvement months later. In that case, the fellow eye improved from 235 to 119 microns by 3 months. Notably, SD-OCT did not show progression to generalized atrophy, except in 1 eye (139–83  $\mu$ m), but in that case, there was initial severe ganglion cell layer atrophy. The lack of conversion to optic atrophy in our series suggests that ICP normalization after stenting is rapid enough to protect optic nerves from irreparable damage and corroborates one other study which noted normal RNFL thickness within 3 months (31), and another which demonstrated improved RNFL thickness in 8/11 stented patients (32).

Importantly, our data demonstrated a robust improvement in Humphrey visual fields. Future studies evaluating venous sinus stenting should continue to analyze visual field improvement quantitatively.

Resolution or improvement in TVO, diplopia, and PST occurred in all our patients and headache in the majority (84.7%). This was associated with an improvement in QoL.

Two patients (15%) did demonstrate persistent headaches despite stenting, but in both cases, these were no longer positional, and ICP and optic disc edema normalized.

#### *Fulminant Papilledema*

Three patients underwent stenting because of fulminant papilledema and vision loss. All 6 eyes experienced VF improvement, and none developed optic atrophy. This favorable outcome is consistent with the report of Elder et al (33). Our results suggest that even in the absence of CSF diversion procedures, venous stenting can offer normalization of ICP of sufficient speed to minimize permanent severe vision loss in fulminant cases of IIH.

#### *Need for Additional Surgical Treatments*

None of our patients required additional surgical treatment to relieve symptoms of ICP. This compares favorably with rates of patients in other series that required CSF shunts after stenting, which were up to 20% (20,34).

#### *Stenting in Context*

Although visual symptoms and papilledema usually improve after stenting, the effect on headaches is more variable. Furthermore, there have been serious complications including subdural hemorrhage. However, the risk of complications or failure compares favorably to alternative surgical procedures for IIH. Although additional prospective studies on this procedure are needed, our findings support a definite role in the treatment options for IIH.

#### *Limitations of Study*

We recognize several limitations to our study. Although data was collected prospectively, with uniform pre- and post-stenting testing, patients served as their own controls



with no randomized alternative therapy. Patient choice to enter the study may have selected for those eager to improve, and placebo effect may have effected symptomatic improvement. Although ICP-lowering medications were reduced or stopped before follow-up LP in most patients, they were not always stopped abruptly post stenting. Improvement may, therefore, have resulted in part from latent effects of these medications, although this is unlikely, given resistance to medication before stenting. Weight loss does not appear to have confounded the results, because, despite counseling, the majority of patients actually gained weight. Finally, the improvements demonstrated at 3 months post stenting do not speak to the long term efficacy of stenting for IIH. A follow-up analysis using data collected at the 2-year mark is planned to address this question.

## CONCLUSION

We present our prospective data after venous sinus stenting for medically-refractory, medication-intolerant, or fulminant IIH, adding to the body of evidence that this procedure is safe and may be considered as an alternative therapy for patients requiring surgical intervention. There remains insufficient evidence to support any surgical procedure for IIH over another, and a large, multicenter, randomized, physician-blinded, head-to-head trial comparing venous stenting to shunting is needed to determine the relative safety and efficacy of these options.

## REFERENCES

1. **Corbett JJ**, Savino PJ, Thompson HS, Kansu T, Schatz NJ, Orr LS, Hopson D. Visual loss in pseudotumor cerebri. Follow-up of 57 patients from five to 41 years and a profile of 14 patients with permanent severe visual loss. *Arch Neurol*. 1982;39:461–474.
2. **Johnson LN**, Krohel GB, Madsen RW, March GA. The role of weight loss and acetazolamide in the treatment of idiopathic intracranial hypertension (pseudotumor cerebri). *Ophthalmology*. 1998;105:2313–2317.
3. **NORDIC Idiopathic Intracranial Hypertension Study Group Writing Committee**, Wall M, McDermott MP, Kiebertz KD, Corbett JJ, Feldon SE, Friedman DI, Katz DM, Keltner JL, Schron EB, Kupersmith MJ. Effect of acetazolamide on visual function in patients with idiopathic intracranial hypertension and mild visual loss: the idiopathic intracranial hypertension treatment trial. *JAMA*. 2014;311:1641–1651.
4. **Thambisetty M**, Lavin PJ, Newman NJ, Bioussé V. Fulminant idiopathic intracranial hypertension. *Neurology*. 2007;68:229–232.
5. **Wall M**, George D. Idiopathic intracranial hypertension. A prospective study of 50 patients. *Brain*. 1991;114:155–180.
6. **Quincke H**. Meningitis serosa. *Samml Klin Vortr, Leipzig* 67. *Inn Med*. 1893;23:655.
7. **Corbett JJ**, Thompson HS. The rational management of idiopathic intracranial hypertension. *Arch Neurol*. 1989;46:1049–1051.
8. **Farb RI**, Vanek I, Scott JN, Mikulis DJ, Willinsky RA, Tomlinson G, terBrugge KG. Idiopathic intracranial hypertension: the prevalence and morphology of sinovenous stenosis. *Neurology*. 2003;60:1418–1424.
9. **King JO**, Mitchell PJ, Thomson KR, Tress BM. Cerebral venography and manometry in idiopathic intracranial hypertension. *Neurology*. 1995;45:2224–2228.
10. **Higgins JNP**, Owler BK, Cousins C, Pickard JD. Venous sinus stenting for refractory benign intracranial hypertension. *Lancet*. 2002;359:228–230.
11. **Higgins JNP**, Cousins C, Owler BK, Sarkies N, Pickard JD. Idiopathic intracranial hypertension: 12 cases treated by venous sinus stenting. *J Neurol Neurosurg Psychiatry*. 2003;74:1662–1666.
12. **Owler BK**, Parker G, Halmagyi GM, Dunne VG, Grinnell V, McDowell D, Besser M. Pseudotumor cerebri syndrome: venous sinus obstruction and its treatment with stent placement. *J Neurosurg*. 2003;98:1045–1055.
13. **Donnet A**, Metellus P, Levrier O, Mekkaoui C, Fuentes S, Dufour H, Conrath J, Grisoli F. Endovascular treatment of idiopathic intracranial hypertension: clinical and radiologic outcome of 10 consecutive patients. *Neurology*. 2008;70:641–647.
14. **Bussi re M**, Falero R, Nicolle D, Proulx A, Patel V, Pelz D. Unilateral transverse sinus stenting of patients with idiopathic intracranial hypertension. *AJNR Am J Neuroradiol*. 2010;31:645–650.
15. **Ahmed RM**, Wilkinson M, Parker GD, Thurtell MJ, Macdonald J, McCluskey PJ, Allan R, Dunne V, Hanlon M, Owler BK, Halmagyi GM. Transverse sinus stenting for idiopathic intracranial hypertension: a review of 52 patients and of model predictions. *AJNR Am J Neuroradiol*. 2011;32:1408–1414.
16. **Albuquerque FC**, Dashti SR, Hu YC, Newman CB, Teib M, McDougall CG, ReKate HL. Intracranial venous sinus stenting for benign intracranial hypertension: clinical indications, technique, and preliminary results. *World Neurosurg*. 2011;75:648–652.
17. **He C**, Ji X, Wang L, Liu X, Zhang X, Wang S, Chen J, Ling F. [Endovascular treatment for venous sinus stenosis in idiopathic intracranial hypertension]. *Zhonghua Yi Xue Za Zhi*. 2012;92:748–751.
18. **Kumpe DA**, Bennett JL, Seinfeld J, Pelak VS, Chawla A, Tierney M. Dural sinus stent placement for idiopathic intracranial hypertension. *J Neurosurg*. 2012;116:538–548.
19. **Fields JD**, Javedani PP, Falardeau J, Nesbit GM, Dogan A, Helseth EK, Liu KC, Barnwell SL, Petersen BD. Dural venous sinus angioplasty and stenting for the treatment of idiopathic intracranial hypertension. *J Neurointerv Surg*. 2013;5:62–68.
20. **Radvany MG**, Solomon D, Nijjar S, Subramanian PS, Miller NR, Rigamonti D, Blitz A, Gailloud P, Moghekar A. Visual and neurological outcomes following endovascular stenting for pseudotumor cerebri associated with transverse sinus stenosis. *J Neuroophthalmol*. 2013;33:117–122.
21. **Riggeal BD**, Bruce BB, Saindane AM, Ridha MA, Kelly LP, Newman NJ, Biouss  V. Clinical course of idiopathic intracranial hypertension with transverse sinus stenosis. *Neurology*. 2013;80:289–295.
22. **Rohr A**, D rner L, Stingele R, Buhl R, Alfke K, Jansen O. Reversibility of venous sinus obstruction in idiopathic intracranial hypertension. *AJNR Am J Neuroradiol*. 2007;28:656–659.
23. **King JO**, Mitchell PJ, Thomson KR, Tress BM. Manometry combined with cervical puncture in idiopathic intracranial hypertension. *Neurology*. 2002;58:26–30.
24. **Bono F**, Giliberto C, Mastrandrea C, Cristiano D, Lavano A, Fera F, Quattrone A. Transverse sinus stenoses persist after normalization of the CSF pressure in IIH. *Neurology*. 2005;65:1090–1093.
25. **Connor SEJ**, Siddiqui MA, Stewart VR, O'Flynn EA. The relationship of transverse sinus stenosis to bony groove dimensions provides an insight into the aetiology of idiopathic intracranial hypertension. *Neuroradiology*. 2008;50:999–1004.
26. **Stevens SA**, Previte M, Lakin WD, Thakore NJ, Penar PL, Hamschin B. Idiopathic intracranial hypertension and transverse sinus stenosis: a modelling study. *Math Med Biol*. 2007;24:85–109.
27. **Ahmed R**, Friedman DI, Halmagyi GM. Stenting of the transverse sinuses in idiopathic intracranial hypertension. *J Neuroophthalmol*. 2011;31:374–380.



28. **Levitt MR**, Albuquerque FC, Ducruet AF, Kalani MYS, Mulholland CB, McDougall CG. Venous sinus stenting for idiopathic intracranial hypertension is not associated with cortical venous occlusion. *J Neurointerventional Surg.* 2016;8:594–595.
29. **Sinclair AJ**, Kuruvath S, Sen D, Nightingale PG, Burdon MA, Flint G. Is cerebrospinal fluid shunting in idiopathic intracranial hypertension worthwhile? A 10-year review. *Cephalalgia.* 2011;31:1627–1633.
30. **Alsuhaibani AH**, Carter KD, Nerad JA, Lee AG. Effect of optic nerve sheath fenestration on papilledema of the operated and the contralateral nonoperated eyes in idiopathic intracranial hypertension. *Ophthalmology.* 2011;118:412–414.
31. **Alessi G**, Levrier O, Conrath J, Hoffart L, Donnet A, L'attention L, Metellus P, Giorgi R, Matonti F, Ridings B. [Optical coherence tomography in following up papilledema in idiopathic intracranial hypertension treated with lateral sinus stent placement]. *J Fr Ophtalmol.* 2010;33:637–648.
32. **Smith KA**, Peterson JC, Arnold PM, Camarata PJ, Whittaker TJ, Abraham MG. A case series of dural venous sinus stenting in idiopathic intracranial hypertension: association of outcomes with optical coherence tomography. *Int J Neurosci.* 2016;29:1–9.
33. **Elder BD**, Rory Goodwin C, Kosztowski TA, Radvany MG, Gailloud P, Moghekar A, Subramanian PS, Miller NR, Rigamonti D. Venous sinus stenting is a valuable treatment for fulminant idiopathic intracranial hypertension. *J Clin Neurosci.* 2015;22:685–689.
34. **Ducruet AF**, Crowley RW, McDougall CG, Albuquerque FC. Long-term patency of venous sinus stents for idiopathic intracranial hypertension. *J Neurointerv Surg.* 2014;6:238–242.